



Avoiding dermal filler complications

Richard N. Sherman, MD*

Department of Dermatology, Tulane University School of Medicine, The Skin Institute of New Orleans, New Orleans, LA 70115, USA

Abstract Age-related volume loss; increased skin laxity, fat loss, and redistribution; and diminished support from underlying muscle and bone result in the observable and sometimes profound changes seen in the aging face. Aging also is associated with functional changes in the skin, such as dermal atrophy with diminished fibroblastic activity, decreased collagen production, and altered elastin. Dermal fillers, such as bovine, human, and purified porcine collagen; hyaluronic acids; calcium hydroxylapatite; and injectable medical devices (eg, poly-L-lactic acid), are used commonly for facial rejuvenation. Soft-tissue augmentation with dermal fillers and injectable medical devices has gained widespread acceptance as an alternative to more aggressive, invasive treatment of the aging face. Technique, knowledge, expertise with fillers, proper patient assessment, a well-formulated treatment plan with access to agents for superficial, moderate, and deep rhytides, and volume restoration provide the necessary ingredients for optimal soft-tissue augmentation while minimizing complications.

© 2009 Elsevier Inc. All rights reserved.

Soft-tissue volume loss, particularly in the orbital and malar areas, is one of the hallmarks of the aging face. Age-related volume loss, increased skin laxity, fat loss and redistribution, and diminished support from underlying muscle and bone result in the observable and sometimes profound changes seen in the aging face. These changes may manifest clinically as glabellar and forehead rhytides, brow ptosis, excess skin of the upper and lower eyelids, descent of the malar fat pad, prominence of the nasojugal folds (tear troughs), deepening of the nasolabial folds, perioral rhytides, jowling, and midneck hollowing.^{1,2} In addition to structural changes, aging is also associated with functional changes in the skin, such as dermal atrophy with diminished fibroblastic activity, decreased collagen production, and altered elastin.

Collagen and elastin are part of the supportive network of the dermis, and depletion and alteration of these substances results in dermal volume loss, decreased resiliency and strength, and increased skin fragility and wrinkling.¹

Dermal fillers, such as collagen (bovine, human, and purified porcine), hyaluronic acids (HAs), calcium hydroxylapatite (CaHA), and injectable medical devices such as poly-L-lactic acid (PLLA) microspheres, are commonly used for facial rejuvenation. Most dermal fillers are *passive* space-filling agents; however, other more deeply implanted agents, such as CaHA and PLLA, are *active* products that are capable of increasing fibroblast activity, which is thought to stimulate neocollagenesis. All of these products have a place in facial rejuvenation, whether used solely or combined. Technique, knowledge, and expertise with fillers, proper patient assessment, and a well-formulated treatment plan with access to agents for superficial, moderate, and deep rhytides and volume restoration provide the necessary ingredients for optimal cosmesis.

* Tel.: +1 504 899 7159.

E-mail address: rshermanmd@cox.net.

Dermal fillers and injectable medical devices

The ideal filling agent should be safe, effective, easily administered, stored at room temperature, and long-lasting. In terms of efficacy, a dermal filler or injectable medical device should reliably restore facial volume with reproducible results. A safe injectable is not allergenic, carcinogenic, or teratogenic, and will not migrate once injected. Ideally, the filler should be associated with few adverse effects and complications for minimal, if any, downtime. Commonly used dermal fillers and injectable medical devices include the collagens, HAs, CaHA, and injectable PLLA.

Collagen

Bovine and human collagens are relatively light, nonviscous fillers and include Zyderm 1, Zyderm 2, Zyplast, CosmoDerm 1, CosmoDerm 2, and CosmoPlast (Allergan, Inc, Irvine, California). Zyderm 1, Zyderm 2, and Zyplast are purified, fibrillar suspensions of bovine collagen in a saline solution containing lidocaine (Table 1).³ Skin testing is required. Zyderm 1 and Zyderm 2 are injected into the superficial papillary dermis using a 30- or 32-gauge needle for treatment of fine lines and wrinkles. These formulations of collagen are light, nonviscous, and flow easily. Injection of Zyderm 1 and Zyderm 2 should be overcorrected (1.5 to 2.0 times the depth of the deformity) because the saline and lidocaine components are reabsorbed within 24 hours.

Zyplast, lightly cross-linked with glutaraldehyde, is a larger collagen implant that is less susceptible to degradation. Zyplast is injected using a 30-gauge needle into the middle and deep reticular dermis to correct deeper lines and wrinkles or for lip augmentation. Zyderm 1, Zyderm 2, and Zyplast are formulated with lidocaine 0.3% for pain reduction and require refrigerated storage. The bovine collagens Zyderm 1 and Zyderm 2 may be layered over Zyplast.⁴

The human collagen dermal fillers CosmoDerm and CosmoPlast are nonimmunogenic, which eliminates the need for skin testing. These products, also relatively light and nonviscous, flow easily. Analogous to Zyderm and Zyplast, CosmoDerm is injected into the superficial papillary dermis using a 30- or 32-gauge needle for fine lines. CosmoPlast, cross-linked with glutaraldehyde, is injected into the middle or deep reticular dermis using a 30-gauge needle for deeper

lines and wrinkles. Overcorrection is necessary with CosmoDerm, due to reabsorption of saline and lidocaine. The human collagen fillers may also be used together, with CosmoDerm layered over CosmoPlast.⁴

Injectable purified porcine collagen (Evolve Collagen Filler, ColBar LifeScience Ltd, Rehovot, Israel; and OrthoNeutrogena, Louisville, Kentucky) was approved by the United States Food and Drug Administration (FDA) in June 2008 for treatment of moderate to deep facial lines and wrinkles. A skin challenge hypersensitivity study of Evolve, in which patients received one injection of Evolve (0.1 mL) in the left forearm, followed by one injection in the right forearm 2 weeks later, showed no reactions indicating hypersensitivity up to 30 days after the second injection. Intradermal skin testing is not required because of the very low potential for hypersensitivity.^{5,6} Results of a split-face, noninferiority study of efficacy comparing the corrective response of Evolve with that of HA (Restylane, Medicis Aesthetics Inc, Scottsdale, Arizona) injections into the nasolabial folds showed that 97% of patients maintained the cosmetic effects of Evolve for at least 6 months.⁷ Histologic analysis of Evolve implants *in vivo* demonstrated fibroblast migration and ingrowth 1 month after implantation and subsequent neocollagenesis and neovascularization in the implants.⁸

Evolve (3.5% purified porcine type I collagen suspended in phosphate-buffered saline for injection) is uniquely cross-linked with D-ribose using Glymatrix technology (ColBar LifeScience Ltd) to prevent degradation and prolong its cosmetic effects.⁹ It is supplied in volumes of 0.5 or 1 mL in prefilled, single-use, Luer-lock glass syringes. Injection is recommended using a 27-gauge 0.5-inch needle.

In the author's experience, Evolve is ideal for correction of moderate to deep facial lines and wrinkles, such as the nasolabial folds and marionette lines, or for limited areas of mild to moderate volume loss such as the submalar region, lateral chin, and the prejowl sulcus. The flow characteristics allow for easy injection into the middle to deep dermis using a linear retrograde tunneling technique; immediate postinjection massage maintains uniform distribution. Bruising tends to be minimal because of the platelet-aggregating effects characteristic of most collagen fillers.¹⁰

Although skin testing is not required, Evolve should not be injected in patients with a history of porcine allergy or

Table 1 Injection parameters for collagen-based dermal fillers

Product	Indication	Recommended needle size (gauge)	Depth of injection	Skin testing required
Zyderm	Wrinkles, fine lines	30 or 32	Superficial/papillary dermis	Yes
Zyplast	Deep folds, wrinkles, lip augmentation	30	Mid to deep dermis	Yes
CosmoDerm	Wrinkles, fine lines	30	Superficial/papillary dermis	No
CosmoPlast	Deep folds, wrinkles, lip augmentation	30	Mid to deep dermis	No
Evolve	Moderate to deep facial wrinkles and folds	27	Mid to deep dermis	No

serious anaphylactic or recurrent allergic reactions. Its use in patients with a history of allergy to bovine collagen has not been studied. Evolence should not be injected into the periorbital area or lips.¹¹

A lighter formulation of purified porcine type I collagen (Evolence Breeze; ColBar LifeScience Ltd), scheduled to be available soon in the United States, is intended for superficial wrinkle corrections to the upper to middle dermis and for lip augmentation.¹² Evolence is stored at room temperature.

HA fillers

HA forms the fluid matrix of the connective tissue in which collagen, elastin, and other components are embedded. In its natural form, HA has a half-life of only a few days and must therefore be chemically stabilized through cross-linking to function as a dermal filler.¹³ HA gels are highly hydrophilic and have the unique property of dynamic viscosity, whereby their viscosity increases with decreasing shearing force. Thus, they are relatively fluid under injection pressure, but form a stable viscous gel, unlikely to migrate, once implanted.⁴ The current FDA-approved HA-based dermal fillers include Hylaform, Juvéderm Ultra, and Juvéderm Ultra Plus (Allergan, Inc), and Restylane and Perlane (Medicis Aesthetics Inc; Table 2). (Two other HA fillers, Hylaform Plus and Captique [Allergan, Inc], are no longer available.)¹⁴ Although most HAs can be injected with a 30-gauge needle, a 27-gauge needle is recommended for injection of the more viscous or larger, more particulate varieties of HAs, such as Juvéderm Ultra Plus and Perlane. HAs do not require skin testing and are stored at room temperature.

Calcium hydroxylapatite

CaHA is the primary mineral component of bone. An injectable formulation of CaHA (Radiesse; BioForm Medical, Inc, San Mateo, California) is approved by the FDA for long-lasting correction of moderate to severe nasolabial folds. The CaHA microspheres (25 to 45 μm) are suspended

in an aqueous gel carrier. Initially, both act as filler. After 2 to 3 months, however, the water-based vehicle will degrade, leaving behind the CaHA microspheres that stimulate neocollagenesis. CaHA is supplied in prefilled 1.3- or 0.3-mL syringes. CaHA is highly viscous and is injected using a 27-gauge needle into the deep dermis or, for volume restoration, at or below the dermal subcutaneous junction. Injections may be painful because of the larger particle size, high viscosity, absence of anesthesia in prefilled syringes, and needle size. CaHA is stored at room temperature and does not require skin testing.

Injectable PLLAs

Injectable PLLA (Sculptra; Dermik Laboratories, Bridgewater, New Jersey) is often described as a deep-dermal filler. PLLA is more accurately viewed as an FDA-approved injectable medical device implanted at or below the level of the dermal subcutaneous junction for global volumetric enhancement of the lower two-thirds of the face in patients with lipoatrophy associated with HIV infection. Off-label cosmetic use is common. The longevity of PLLA (18 to 24 months) is because of the slow degradation kinetics of the large, irregularly shaped PLLA microparticles, which measure 40 to 63 μm and have a high molecular weight of 140,000 Da.¹⁵

Injectable PLLA is supplied as a sterile, freeze-dried powder with a shelf life of 2 years at room temperature. It requires reconstitution to form the highly viscous, particulate hydrogel that dictates injection with a 25- or 26-gauge needle. Reconstitution is performed about 24 hours before use with the addition of 6 to 7 mL of sterile bacteriostatic water for injection and 1 mL of lidocaine 1% or 2%, with or without epinephrine, added slowly just before use. Alternative ratios of sterile bacteriostatic water and lidocaine may be used. In the author's experience, efficacy is not compromised by the current trend to use a higher reconstitution volume of 7 to 8 mL per vial.

Reconstituted PLLA may be stored as a multidose vial at room temperature for 30 days. Occasionally, a quick mix is required and may be accomplished within 2 hours. In such cases, the reconstituted vial may be kept at body temperature, as in a pant-leg pocket, to facilitate the suspension process. Patient assessment and mapping skills, serial injection sessions in accordance with the mantra of PLLA ("treat, wait, and assess"), and appropriate training on injection technique and the principles of volume restoration are necessary for PLLA injection. PLLA is nonimmunogenic, negating skin testing.

Injection techniques

The most common injection techniques used for facial augmentation are serial puncture and retrograde linear

Table 2 United States Food and Drug Administration–approved hyaluronic acid dermal fillers

Product	Recommended needle size (gauge)	Depth of injection
Hylaform	30	Mid to deep dermis
Restylane	30	Mid to deep dermis
Juvéderm Ultra	30	Mid to deep dermis
Juvéderm Ultra Plus	27	Mid to deep dermis
Perlane	27	Deep dermis to superficial subcutaneous space

threading or tunneling (Figure 1).^{14,16} The serial puncture technique is often used when superficial fine lines or areas of thinner skin are injected. In such cases, the serial puncture technique is performed as follows:

- The skin may be held taut with the nondominant hand, while the needle tip, bevel up, approaches almost parallel to the skin surface at an angle of 10° to 30°.
- Once the needle is inserted into the superficial dermis, a small aliquot of product is delivered, and the needle is withdrawn.³ The process is repeated along the entire length of the fine line or wrinkle.
- Tissue massage immediately after implantation may help avoid papules, nodules, or contour irregularities.¹⁷

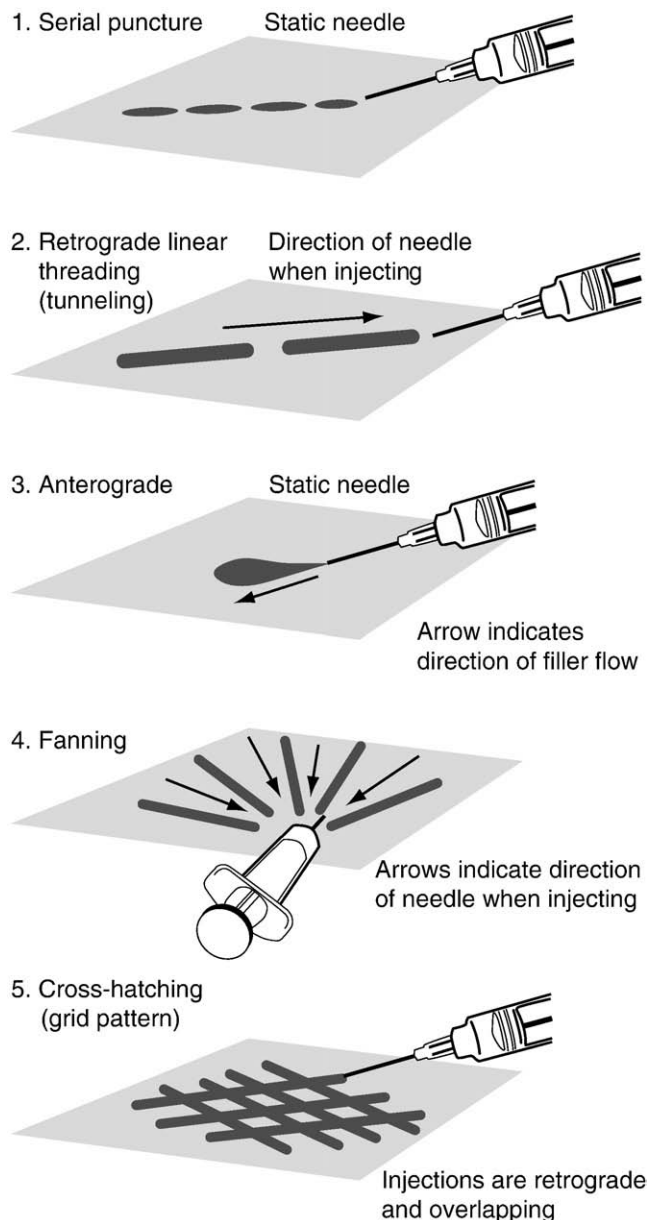


Fig. 1 Injection techniques. (Adapted with permission from The McGraw-Hill Companies, Inc © 2007.¹⁶)

The serial puncture technique may also be used with products like Zyplast, CosmoPlast, and the HAs on moderate to deep wrinkles in areas such as the nasolabial folds. In such cases, the needle approach is at a 45° to 90° angle to enter the middle to deep reticular dermis or the dermal subcutaneous space.³

When the linear threading or tunneling technique is used, the needle enters the skin, bevel up, at a 30° to 45° angle and is fully inserted to the hub at the appropriate depth, dictated by the nature of the defect and the dermal filler selected. The filler is then uniformly distributed, in a retrograde fashion, into the created tunnel, as the needle is slowly withdrawn from the skin.³ In the author's experience, it is best to stop the injection for all dermal fillers before needle withdrawal to avoid leakage and wasted product or superficial implantation that may lead to papule or nodule formation. The filler also may be delivered as the needle is advanced using an anterograde injection technique.¹⁸

With purified porcine collagen and volumizing agents such as PLLA, CaHA, and the HA Perlane, the retrograde linear threading or tunneling technique is most commonly used and preferred. This injection technique for PLLA is performed using a 25-gauge 1-inch or a 26-gauge 0.5-inch needle inserted, bevel up, at a 30° to 45° angle at or below the level of the dermal subcutaneous junction.^{15,19} There is decreased resistance with passage through the dense dermis into the yielding subcutaneous fat. At this level, the angle is reduced, and the needle is completely inserted to the hub and parallel to the skin surface. Small PLLA aliquots of 0.025 to 0.1 mL are injected in a retrograde, linear fashion as the needle is withdrawn from the skin. The injection is stopped before the needle is removed from the skin to avoid superficial dermal implantation.

Immediate and aggressive massage after several injections or after completion of a cosmetic unit is best to ensure homogeneous distribution. The author's patients are instructed to massage 5 minutes twice daily for 7 days to further minimize formation of papules or nodules. Patients cannot overmassage, and the PLLA will not migrate with massage.

Some injectors use the depot method of injection for specific sites such as the orbital rim, temples, and the zygomatic arch, delivering small aliquots of PLLA deeply, just above the periosteum.¹⁹ Depot injections are equivalent to bolus injections, which are more likely to cause a papule or nodule and should therefore be used with caution.

When volumizing agents such as PLLA, CaHA, and Perlane are being injected, the triad of "depth, volume, and distribution" should be remembered. The appropriate depth is at or below the dermal subcutaneous junction. Small aliquots of 0.025 to 0.1 mL are injected per retrograde tunnel and spaced in a uniform distribution 2 to 4 mm apart with cross-hatching in a grid like pattern. For global volumetric soft-tissue enhancement of the lower two thirds of the face, areas such as the middle and lateral cheeks, the fanning technique may be used to inject the submalar region and the

lateral chin to minimize needle sticks and for efficiency. With fanning, the needle is inserted, bevel up, through a single entry point and then pivoted to create a series of linear tunnels in a fanlike pattern. A retrograde thread of the volumizing agent is placed within each tunnel, and the volume is tapered as the needle approaches the pivot point to avoid excess accumulation and possible nodule formation at the pivot point.¹⁵ Cross-fanning perpendicular to the original fanned tunnels may be performed as a modified version of cross-hatching.

General guidelines for filler injection

The target area or cosmetic unit requiring treatment and nature of the defect—whether a fine line or a moderate to deep wrinkle—or area of volume loss directs an injector's choice for soft-tissue augmentation. The characteristics of the filling agent, such as molecular weight, particle size, viscosity, and recommended level of implantation, influence the depth, volume, and distribution of the chosen filler. In most areas of the face, the dermis is less than 1 mm thick.²⁰ Dermal thickness may vary in different regions of the face, however, affecting injection depth and filler choice. The dermis, for example, is extremely thin in the periorbital and eyelid areas, the nasal dorsum, and the cutaneous lip. Successful treatment of such areas depends on selection of an appropriate superficial dermal filler. A lighter product of smaller particle size and lower viscosity is the best choice, with adjustments made in depth, volume, and distribution of the filler for the anatomic variation in dermal thickness.

For fine lines, bovine and human-derived collagens, such as Zyderm or CosmoDerm, are commonly used and may be layered in the papillary and middle dermis for optimal results. These forms of collagen may be used alone or with botulinum toxin type A (Botox Cosmetic, Allergan, Inc) to treat fine lines and wrinkles of the perioral area (eg, the cutaneous upper lip), the periorbital area, and glabella. In the author's experience, a combination treatment is most effective with botulinum toxin injected into the cosmetic unit 2 weeks before filler injection, allowing complete onset. Zyderm or CosmoDerm may then be injected into any fine or etched lines that may remain.

When injecting the cutaneous upper lip, some injectors prefer a serial puncture technique to inject vertical rhytides following the wrinkle line. Care should be taken not to greatly overcorrect, giving the wrinkle line a ridged appearance. The best technique for vertical lip rhytides of the cutaneous upper lip, whether superficial or deep, may be injections perpendicular to the wrinkle line using the retrograde linear threading technique. The injector begins about 1 mm superior to the mucocutaneous junction of the lip, just lateral to the midline/philtrum, and injects in a medial to lateral fashion from the midline to the oral commissure. Injections should be parallel to the mucocuta-

neous junction. Injections are layered beginning at the inferior aspect of the cutaneous upper lip and then moving superiorly. Small, titrated volumes are used to maintain the natural contour and profile of the cutaneous upper lip. Gentle massage is used to smooth.

This method allows and emphasizes treatment of the entire cosmetic unit—the cutaneous upper lip—and will address not only the vertical wrinkle lines but also dermal volume loss. This method also serves to blend the cutaneous upper lip into the nasolabial fold for a more harmonious result.

Collagen products (Zyplast and CosmoPlast) and HA products (Hylaform, Restylane, and Juvéderm) are commonly layered throughout the middle and deep aspects of the dermis. These slightly heavier, particulate, or more viscous fillers may be used for soft-tissue augmentation of moderate to deep perioral wrinkles, nasolabial folds or marionette lines, or for lip augmentation, by using the serial puncture or linear threading techniques. Zyplast should be avoided in the glabella. The rich vascular network in this area increases the risk for pressure necrosis, which may occur with any implant of larger particle size, high molecular weight, or viscosity, and for intravascular injection with subsequent microembolization and skin necrosis.²⁰

Although lip augmentation may be performed with any of these products, the HAs are most commonly used today. Restylane is a good choice for individuals who like a well-defined vermilion border/white roll. Overfill or overcorrection of the vermilion border/white roll is not recommended. This creates an acute angle at the mucocutaneous junction that appears unnatural. Injection of filler in the vermilion border/white roll may be accomplished with the retrograde linear threading or serial puncture technique within the intradermal or submucosal layer, or both.²¹

A 30-gauge 0.5-inch needle is used for most lip injections. Augmentation of the vermilion border/white roll begins just lateral to the midline/philtrum with full insertion of the needle into the middle to deep dermis, injecting in a medial to lateral fashion from the midline to the oral commissure.²¹ Immediate, gentle massage keeps the implant smooth. The opposite side is then filled, followed by treatment of the Cupid's bow and philtrum, if desired. The lower lip is treated in a similar fashion.

Once the vermilion border/white roll is complete, the serial puncture technique, with frequent massage to avoid nodules, is used for soft-tissue augmentation of the body of the upper and lower lips. Treatment of all anatomic components of the aging lips, including the cutaneous lip for vertical lines and volume loss, the vermilion border/white roll for definition, and the body of the lips for fullness, will provide the best overall cosmetic result.

For deeper rhytides associated with underlying volume loss, correction may be best achieved with implantation at or below the level of the dermal subcutaneous junction. PLLA, CaHA, and Perlane may be implanted for volume restoration. Although PLLA is best used for global volumetric soft-tissue

enhancement of the lower two-thirds of the face, this injectable medical device, as well as CaHA and Perlane, may also be used for the correction of moderate to deep nasolabial folds. The injection technique is similar for all three agents.

For the correction of nasolabial folds and depressions with CaHA, a 27-gauge 0.5-inch needle is inserted, bevel up, midway along the nasolabial fold and advanced parallel to the skin surface within the deep dermis or at the dermal subcutaneous junction. The needle, completely inserted to the hub, should reach the superior aspect of the nasolabial fold. A retrograde linear threading or tunneling technique is used to inject the CaHA as the needle is withdrawn. Just before the needle would exit the skin at the initial entry site, it is redirected medially to deliver a second retrograde linear thread of CaHA. On completion, the needle is withdrawn and reinserted at the base of the nasolabial fold, lateral to the oral commissure, and directed just beyond the initial entry site. CaHA is then implanted in a retrograde fashion (Figure 2).²²

Injectable PLLA and CaHA should not be used for augmentation of the vermilion border/white roll or body of the lips, secondary to an increased risk of nodule formation. PLLA, however, may be injected into the cutaneous upper lip for a lip lift.¹⁵ As with other fillers used in anatomic regions with circular or dynamic sphincteric muscles (eg, the orbicularis oculi, orbicularis

oris), pretreatment 2 weeks before with botulinum toxin type A may minimize nodule formation.

Rejuvenation of the periorbital region with fillers is challenging and reserved for advanced injectors. The aging eyelid is characterized by three soft-tissue depressions: one at the septal confluence (ie, the junction of the inferior orbital septum and tarsal plate), the second at the inferior orbital rim, and the third overlying the zygomaticomalar ligament.^{23,24} Dermal fillers placed along the inferior orbital rim may help soften the transition between the orbital and midface fat and may also improve hollows at the septal confluence and the zygomaticomalar midface depression.²³ Along the inferior aspect of the orbital rim, injections are performed deep to the orbicularis muscle or just overlying the periosteum. Small aliquots (0.025 to 0.05 mL) of PLLA and HA are injected using the retrograde linear tunneling technique. Some injectors may cautiously use the depot method along the inferior aspect of the orbital rim. Massage is performed to aid in uniform distribution and continued posttreatment with PLLA. Undercorrection is the rule, followed by serial injection several weeks later for optimal correction.

At the septal confluence, the needle should be oriented in a horizontal manner to avoid orbital perforation. For the zygomaticomalar depression, injections of HAs, such as Perlane, or PLLA may be layered at or below the dermal subcutaneous junction for volumization. In the author's practice, CaHA and HAs are not commonly used for periorbital rejuvenation; PLLA is preferred.

Layering of a filler, or fillers, may help achieve optimal correction. To enhance overall tissue volume, a volumizing agent, such as PLLA or CaHA, for example, may be layered during an injection session in the dermal subcutaneous space, throughout the subcutaneous fat layer, or just above the periosteum. Once this foundation is established, finer lines and wrinkles may be addressed by using a more superficial dermal filler at the same injection session for an immediate effect or planned as an additional procedure after the effects of volumization are realized.

Knowledge of filler characteristics, anatomy, and wrinkle/volume assessment allow the injector to choose the best fillers for optimal results. The superficial injection of a heavy product of larger particle size or a highly viscous filler, for example, may result in nodule formation or contour irregularities.¹⁷ Injection of a lighter product of smaller particle size or a less viscous filler for correction of volume loss will lead to undercorrection.³ Fine lines are best treated with the superficial injection of lighter products of smaller particle size or fillers with lower viscosity, whereas moderate to deep wrinkles may be managed with a middle to deep dermal injection of heavier products of larger particle size or fillers with higher viscosity. Volume restoration for dermal atrophy, fat loss, and deeper structural changes related to aging is best handled with deeper implantation at or below the level of the dermal subcutaneous junction, using active fillers that stimulate neocollagenesis, such as PLLA and CaHA or the HA Perlane.

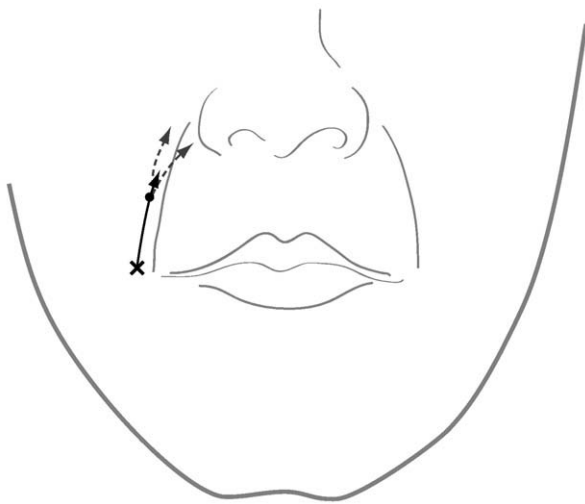


Fig. 2 Injection technique for nasolabial fold correction with calcium hydroxylapatite.²² Linear threading technique: the needle is inserted parallel to the skin at the midpoint of the nasolabial fold (solid circle), then advanced parallel to the skin surface in the dermal subcutaneous space; filler is delivered as the needle is withdrawn. Just before the needle exits the skin, it is reoriented medially and advanced, and the injection process is repeated, thus placing 2 threads in a V configuration (dotted lines). The needle is then withdrawn completely, reinserted at the base of the fold (X), and advanced to just beyond the previous insertion point (solid circle); the process is then repeated a second time (solid line). (Adapted with permission from the American Academy of Dermatology, Inc; Mosby, Inc © 2007.²²)

Needle and syringe size

Each manufacturer has recommendations regarding the preferred syringe and needle for injection. A number of injectable dermal fillers (collagens, HAs, and CaHA) are available in kits containing prefilled Luer-lock syringes and fine-gauge needles (30- or 27-gauge 0.5-inch) for convenient injection. The smallest needle that will deliver the filler at the appropriate depth without compromising efficacy should be used. In the author's experience, even the more viscous fillers, such as Perlane and Evolence, may be injected without compromise using a 30-gauge needle, providing a highly controlled injection of small aliquots. Smaller-bore needles, with an inherently greater resistance to flow, naturally allow for a more conservative injection volume. Some injectors may become frustrated with manufacturer-recommended needles because of clogging or a reduced flow rate and opt for a larger-bore needle for ease of injection. This needle switch should be approached cautiously. With a larger-bore needle and increased flow rate, injection pressure must be adjusted to avoid complications associated with a bolus injection.

PLLA injection has the most variable syringe and needle options because this product is not supplied in prefilled syringes. The manufacturer recommends a 3-mL Luer-lock syringe, providing a uniform pressure gradient for injection, and a 26-gauge 0.5-inch needle. Some advanced injectors prefer a 1-mL Luer-lock silicone-coated syringe, allowing accurate accounting of small injection volumes of 0.025 to 0.1 mL per injection. The disadvantage of the 1-mL Luer-lock silicone-coated syringe is the potential for rapid flow of PLLA with very little pressure, leading to bolus injection and increased risk for nodule formation. In the author's experience, newly trained PLLA injectors are encouraged to use the 3-mL Luer-lock syringe.

As with syringe variation, an assortment of needle choices (26-gauge 0.5-inch, 25-gauge 0.625-inch, 25-gauge 1-inch, and 25-gauge 1.5-inch) are available when PLLA is injected. In the author's experience, the Terumo syringe with an attached 25-gauge 1-inch needle (Terumo Medical Corp, Elkton, Maryland) works best for appropriate depth, volume, and distribution of PLLA implantation with minimal clogging and optimal flow rate.

Anesthesia

Injection depth, anatomic area, dermal filler viscosity, and patient tolerance to pain may all contribute to the decision for anesthesia. Topical anesthetics and ice packs may minimize the pain of needle sticks and may be all that is required for implantation of superficial dermal fillers or in patients with a high pain tolerance. Human and bovine collagen are premixed with lidocaine. The addition of lidocaine 1% or 2% to PLLA, CaHA, or HA, just before injection, may

supplement pain control. Bilateral infraorbital and mental regional nerve blocks may be necessary, especially for lip augmentation.²¹ Small amounts of local anesthetic may also provide pain relief, but excessive volumes should be avoided to minimize tissue distortion.³

Patient preparation

Correct positioning of the patient for the injection is critical. Patients should be upright or reclined at a 45° angle for the injection. Lying supine may alter gravitational effects on the skin and distort or obscure the defect, increasing the chances of inaccurate correction.^{3,18} Patient assessment and pretreatment mapping with a marking pen or eyebrow pencil while the patient is upright may help ensure a more accurate injection.^{15,18}

Allergy testing

Skin testing may be required before injection of dermal fillers derived from nonhuman sources such as bovine collagen, but is generally not required for fillers derived from synthetic sources, such as PLLA, CaHA, or highly purified HAs. Because a few patients may be hypersensitive to bovine collagen but may not immediately exhibit a clinically relevant response, two negative collagen test results during a 4-week period are required before this product can be used. Although the HAs used in dermal fillers may be derived from avian or bacterial sources, these products are highly purified formulations, and immunologic reactions are rare; therefore, skin testing is not recommended before use. Some physicians may choose to perform skin testing because these agents may be associated with delayed inflammatory skin reactions.^{25,26} Purified porcine collagen (Evolence) uses enzymatic treatment with pepsin to create nonimmunogenic collagen fibers, thus eliminating the need for skin testing.

Patient counseling

Patient satisfaction is the most important end point of successful facial rejuvenation. Proper patient education, informed consent, and realistic expectations are prerequisites for treatment with dermal fillers. Patients who are not willing to tolerate possible complications may not be good candidates for soft-tissue augmentation with dermal fillers or injectable medical devices. Patients are always concerned about downtime with cosmetic procedures and should be warned about the risk of bleeding with injections. Patients are instructed to temporarily discontinue over-the-counter blood thinners, such as vitamin E, aspirin, and nonsteroidal anti-inflammatory drugs, and only with medical clearance, prescribed anticoagulants such as warfarin (Coumadin) or

clopidogrel bisulfate (Plavix, Bristol-Myers Squibb/Sanofi Pharmaceuticals Partnership; Bridgewater, New Jersey).¹⁷

Complications

Although skin infections with dermal filler injections are unusual, a skin assessment before treatment for any active bacterial or viral infection, makeup removal, skin preparation with antibacterial soap (eg, chlorhexidine) or alcohol, or both, and proper attention to clean/sterile technique will further help minimize secondary infections. Patients with a history of perioral or facial herpes simplex virus, or both, should begin systemic antiviral prophylaxis before treatment and continue for 5 to 7 days to prevent a herpes simplex virus outbreak.³ This is important, especially with lip augmentation and with global volumization of the face, where the patient must actively massage after injection, thus risking spread of a herpes simplex virus outbreak beyond the primary site.

The injection of almost any dermal filler may be associated with minor adverse effects, such as injection-site burning, itching, or pain (secondary to stretching of cutaneous nerves), erythema, edema, bruising, or hematoma formation, even with excellent technique. These adverse effects, which can be expected to appear occasionally, tend to occur soon after injection, but are usually temporary and may be managed with ice packs, warm compresses, or watchful waiting; rarely, erythema may persist and require treatment with laser or intense pulsed light.²⁰

Tear-trough deformities and eye rings (ie, upper cheek hollows, infraorbital hollows) are tricky areas to treat with any filler and should be approached cautiously. Improper injection of thin periorbital skin with HAs may lead to the appearance of the Tyndall effect. The Tyndall effect manifests as a bluish or blue-gray color change that is seen when light refraction through the skin changes, as with superficial or excess implantation of clear, viscous HAs.^{27,28}

Overcorrection with HA products in the periorbital area also may cause a puffy, edematous appearance of the lower eyelids because of the hydrophilic nature of the filler. The edema may seem to wax and wane, fluctuating in patients with allergic predispositions or in response to dietary salt intake. Approach patients with festooning (the small baglike protrusions usually located at the inferior-lateral aspect of the lower eyelids/upper cheek) or areas of lymphedema cautiously when using HAs. HAs are highly hydrophilic and may exacerbate the condition.

Given the hydrophilic nature of HAs, it may be best to undercorrect a defect, especially in the periorbital area, and use a serial injection approach for optimal correction. Injection of the tear trough or periorbital region with any dermal filler may also be associated with bruising and subsequent hemosiderin deposition, giving an orange-brown or rusty, stained appearance to the skin that may take months

to resolve on its own. Preinjection ice application, proper injection depth, discontinuation of anticoagulants at least 7 days before injection, and a smooth, gentle technique may help avoid this complication.

Intravascular injection should be avoided. Accidental injection of a dermal filler into the ophthalmic artery through one of its proximal branches (the retinal or posterior ciliary arteries) or distal branches (many of the superficial arteries of the face) may lead to an arterial occlusion with subsequent skin necrosis or, rarely, blindness, regardless of the injection location on the face.²⁹ Aspiration before injection, especially in highly vascular areas, knowledge of the vascular anatomy of the face, and the dynamic nature of the retrograde linear injection technique may help avoid this pitfall. The risk and consequences of an accidental injection into the facial arterial system may also be minimized by controlling injection pressure using small syringes (1 to 3 mL), injecting small volumes (0.1 mL or less), or by using blunt cannulas (if possible) rather than sharp cannulas or needles that may be more likely to perforate a thick-walled vessel.²⁹

Papule or nodule formation, surface irregularities, overcorrection, and asymmetry may result from improper injection technique. For example, a dermal filler may be injected too superficially, leading to surface irregularity or papule formation, or both, or injected at the proper depth but using too much volume (ie, a bolus injection), which may lead to contour irregularity or nodule formation, or both. Massage should be the immediate response to an injection that is too superficial or to an overcorrection. Early massage may help smooth the skin and uniformly distribute the injected filler. Small papules or nodules may sometimes respond to superficial incision and drainage, low-dose intralesional steroid injections, or an injection of hyaluronidase in those related to HAs.³⁰ Persistent papules and superficial surface irregularities may be treated with resurfacing procedures such as spot dermabrasion or laser.²⁰

Self-assessment of one's injection technique and cosmetic results in real time is important for both physician and patient satisfaction. The results of dermal fillers such as collagen and HAs are immediate—what you see is essentially what you get. A product such as PLLA shows an immediate but temporary volume change, with the end result dependent on neocollagenesis. Results with PLLA are highly dependent on injection technique and training for global volumetric enhancement of the face. CaHA shows an immediate effect but also has the delayed benefit of neocollagenesis. Fillers such as PLLA, CaHA, and Evolence should not be injected in the vermilion border or body of the lips secondary to a high rate of nodule formation. Frequent movement in areas of circular or sphincteric muscles (the perioral and periorbital regions) may increase the likelihood for nodule formation, even with recommended fillers.

As previously discussed, areas of high muscle activity may benefit from botulinum toxin type A treatment 2 weeks before soft-tissue augmentation to help reduce the risk of nodule formation.²⁰ Delayed-onset granulomas, a type of

foreign body reaction occurring several months after injection, may be seen with fillers that stimulate neocollagenesis, such as PLLA and CaHA. These granulomas usually appear as asymptomatic nodules and may result from superficial implantation or deeper bolus injection. Specifically with PLLA, proper implant depth (the dermal subcutaneous space or deeper), small injection volumes (0.025 to 0.1 mL per tunnel), uniform distribution, and well-trained technique using retrograde linear tunneling with cross-hatching may collectively help avoid this complication. The author does not recommend depot injections with either product, because he equates the depot method with bolus injection and an increased likelihood that superficial papule or deep nodule formation will occur.

PLLA nodules may be difficult to remove, and asymptomatic nonvisible nodules may be best left alone. The trend for increased reconstitution volumes (7 to 8 mL/vial) and serial treatments spaced farther apart at 6 to 8 weeks for off-label cosmetic use may further decrease the incidence of nodule formation. Symptomatic and visible nodules, which may appear white, tan, skin-colored, or red when acutely inflamed, require treatment. Many physicians have triamcinolone acetonide injectable steroid suspension (Kenalog, Bristol-Myers Squibb) readily available in their offices at standard concentrations of 10 or 40 mg/mL in 5- or 10-mL vials. These may be diluted to lower concentrations with sterile bacteriostatic water for injection or preserved 0.9% normal saline; for example, one could dilute 1 mL of Kenalog 40 mg/mL using 15 mL of sterile bacteriostatic water for injection to create a multidose vial of 2.5 mg/mL (ie, 40 mg Kenalog/16 mL). Triamcinolone acetonide may also be purchased in concentrations of 2 mg/mL or 6 mg/mL. The author prefers to begin treatment of nodules at lower concentrations of 2.0 to 2.5 mg/mL.

When small nodules are to be injected, use either a 1- or a 3-mL Luer-lock syringe and a 30-gauge 0.5-inch needle. The 1-mL syringe may provide the best feedback and control of small volumes required for intralesional steroid injection, whereas the 3-mL syringe allows for increased injection pressure for treatment of harder nodules. Begin with small injection volumes of 0.05 to 0.1 mL per nodule at 2- to 4-week intervals, noting clinical response. Nodules may be dense and solid. If possible, try to penetrate the nodule for a true intralesional injection. If the nodule cannot be penetrated, inject at the nodule perimeter or the deepest aspect of the nodule, or both, to avoid overlying skin atrophy.

For unresponsive nodules at subsequent sessions, one may increase steroid volume (ie, 0.1 to 0.2 mL/nodule). If the nodule is unresponsive, the injector may increase the concentration to a maximum of 5 mg/L for Kenalog or to 6 mg/mL for generic triamcinolone acetonide. Again, begin with small volumes of about 0.05 to 0.1 mL/nodule, then increase the volume at subsequent injection sessions. The author has observed skin atrophy with concentrations of Kenalog of 10 and 40 mg/mL and prefers alternative methods for stubborn nodules.

For nodules that are sometimes rock hard, very large, or unresponsive to intralesional steroid injections alone, use a combination of intralesional steroids, subcision, and rehydration. Perform the intralesional steroid injection first, because the nodules are more easily isolated for localized injection. Subcision and rehydration requires a 25-gauge 1-inch needle attached to a 3-mL Luer-lock syringe containing a mixture of 1 mL of lidocaine 1% (with or without epinephrine) and 2 mL of sterile bacteriostatic water for injection. Simultaneously subcise the nodules with the 25-gauge 1-inch needle and rehydrate with the mixture of lidocaine and sterile bacteriostatic water. The total volume (average, 1 to 3 mL/nodule) of rehydration mixture used may vary with the size and number of nodules. The patient is instructed to massage after treatment, using fingertips or a small vibrator, twice daily for 7 to 10 days. Retreatment is performed at 2- to 4-week intervals depending on clinical response. Aggressive subcision and the number of subcision sessions should be adjusted to avoid causing excessive dermal or subdermal scarring. As an alternative, some nodules may be camouflaged by injecting filler into the area surrounding the nodule. The author's preference in such cases is Perlane, given its longevity and compatible depth of injection. The goal is to minimize the nodules so that they are less symptomatic and less visible.

Some nodules may be a complication of injection technique, but others may appear as an idiopathic immunologic response, in particular after injection of PLLA. This reaction is usually delayed 9 to 12 months after the injection and may present with sudden onset of bilateral, multiple inflammatory nodules or plaques, or both, sometimes associated with edema and a cellulitic appearance of the skin. This reaction is seemingly rare and may be independent of the overall injection volume of PLLA. The author prefers to avoid systemic steroids and the potential rebound upon steroid withdrawal or taper.

Early treatment with oral doxycycline, 100 mg twice daily, improves the acute inflammatory reaction. As the inflammatory response improves, usually over 1 to 3 months, the doxycycline dose may be tapered and eventually discontinued (eg, 100 mg twice daily for 2 to 4 weeks, then 100 mg once daily for 2 to 4 weeks, then 100 mg every other day for 2 to 4 weeks, then discontinued). Additional therapy may include concomitant treatment with nonsteroidal anti-inflammatory drugs, systemic antihistamines, intralesional low-dose steroids, or topical agents, such as pimecrolimus cream 1% (Elidel; Novartis Pharmaceuticals Corp, East Hanover, New Jersey), twice daily. Upon resolution of the inflammatory response, persistent nodules may be managed as previously described. Delayed hypersensitivity reactions are rare with dermal fillers that do not contain animal products. These have been known to occur with HA products and may be attributed to the presence of impurities or high protein content in certain formulations. Current purification techniques have virtually eliminated this risk.¹⁷

Conclusions

Soft-tissue augmentation with dermal fillers and injectable medical devices has gained widespread acceptance as an alternative to more aggressive, invasive treatment of the aging face. Dermal fillers that are matched appropriately to the cosmetic defect, injected with proper technique, and implanted at the optimal depth provide excellent cosmesis with little or no downtime. Inappropriate use of a dermal filler or injectable medical device for a cosmetic procedure may lead to inadequate correction or increase the risk for adverse effects or events. Proper training, knowledge, and expertise using fillers for superficial, moderate, and deep wrinkles and for volume restoration equip the injector with the necessary tools and skills for optimal soft-tissue augmentation while minimizing complications.

Drug names

Botulinum toxin type A: Botox Cosmetic
 Calcium hydroxylapatite: Radiesse BioForm
 Collagen (purified bovine dermal): Zyderm 1, Zyderm 2, Zyplast
 Collagen (human fibroblast culture-derived): CosmoDerm 1, CosmoDerm 2, CosmoPlast
 Collagen (porcine-derived): Evolence Collagen Filler; Evolence Breeze
 Clopidogrel bisulfate: Plavix
 Hyaluronic acid (cross-linked bacterial): Restylane, Perlane, Juvéderm Ultra, Juvéderm Ultra Plus
 Hyaluronic acid (cross-linked avian): Hylaform
 Pimecrolimus cream 1%: Elidel
 Poly-L-lactic acid: Sculptra
 Polymethylmethacrylate: ArteFill
 Triamcinolone acetonide: Kenalog
 Warfarin: Coumadin

References

- Brandt FS, Cazzaniga A. Hyaluronic acid fillers: Restylane and Perlane. *Facial Plast Surg Clin North Am* 2007;15:63-76.
- Friedman O. Changes associated with the aging face. *Facial Plast Surg Clin North Am* 2005;13:371-80.
- Murray CA, Zloty D, Warshawski L. The evolution of soft tissue fillers in clinical practice. *Dermatol Clin* 2005;23:343-63.
- Narins RS, Bowman PH. Injectable skin fillers. *Clin Plast Surg* 2005;32:151-62.
- Shoshani D, Markovitz E, Cohen Y, et al. Skin test hypersensitivity study of a cross-linked, porcine collagen implant for aesthetic surgery. *Dermatol Surg* 2007;33(suppl 2):S152-8.
- EVOLENCE Collagen filler instructions for use. Available at: <http://www.fda.gov/cdrh/pdf7/p070013c.pdf>. Accessed October 9, 2008.
- Narins RS, Brandt FS, Lorenc ZP, et al. A randomized, multicenter study of the safety and efficacy of Dermicol-35 and non-animal-stabilized hyaluronic acid gel for the correction of nasolabial folds. *Dermatol Surg* 2007;33:S213-21.
- Nir E, Goldlust A, Shoshani D, et al. Long-term in vivo evaluation of the safety and efficacy of a new porcine collagen dermal filler cross-linked with ribose. *J Am Acad Dermatol* 2008;AB63:905 [Abstract].
- Pitaru S, Noff M, Blok L, et al. Long-term efficacy of a novel ribose-cross-linked collagen dermal filler: a histologic and histomorphometric study in an animal model. *Dermatol Surg* 2007;33:1045-54.
- Baumann L. Dermal fillers. *J Cosmet Dermatol* 2004;3:249-50.
- Braun M, Braun S. Nodule formation following lip augmentation using porcine collagen-derived filler. *J Drugs Dermatol* 2008;7:579-81.
- Landau M. Lip augmentation and rejuvenation using a novel, porcine collagen-derived filler. *J Drugs Dermatol* 2008;7:236-40.
- Johl SS, Burgett RA. Dermal filler agents: a practical review. *Curr Opin Ophthalmol* 2006;17:471-9.
- Monheit GD. Hyaluronic acid fillers: Hylaform and Captique. *Facial Plast Surg Clin North Am* 2007;15:77-84.
- Sherman RN. Sculptra: the new three-dimensional filler. *Clin Plast Surg* 2006;33:539-50.
- Wolff K, Goldsmith LA, Katz SI, et al. *Fitzpatrick's dermatology in general medicine*. 7th ed. New York, NY: McGraw-Hill Professional; 2007. p. 2381.
- Gladstone HB, Cohen JL. Adverse effects when injecting facial fillers. *Semin Cutan Med Surg* 2007;26:34-9.
- Niamtu III J. The use of Restylane in cosmetic facial surgery. *J Oral Maxillofac Surg* 2006;64:317-25.
- Vleggaar D. Soft-tissue augmentation and the role of poly-L-lactic acid. *Plast Reconstr Surg* 2006;118(suppl):46S-54S.
- Lemperle G. Treatment options for dermal filler complications. *Aesthetic Surg J* 2006;26:356-64.
- Niamtu 3rd J. New lip and wrinkle fillers. *Oral Maxillofac Surg Clin North Am* 2005;17:17-28.
- Alam M, Yoo SS. Technique for calcium hydroxylapatite injection for correction of nasolabial fold depressions. *J Am Acad Dermatol* 2007;56:285-9.
- Finn JC, Cox S. Fillers in the periorbital complex. *Facial Plast Surg Clin North Am* 2007;15:123-32.
- Goldberg RA. The three periorbital hollows: a paradigm for periorbital rejuvenation. *Plast Reconstr Surg* 2005;116:1796-804.
- Bellman B. Immediate and delayed hypersensitivity reactions to Restylane. *Aesthetic Surg J* 2005;25:489-91.
- Grossman KL. Hyaluronic acid gel fillers: hypersensitivity reactions. *Aesthetic Surg J* 2005;25:403-5.
- Hirsch RJ, Brody HJ, Carruthers JD. Hyaluronidase in the office: a necessity for every dermasurgeon that injects hyaluronic acid. *J Cosmet Laser Ther* 2007;9:182-5.
- Hirsch RJ, Narurkar V, Carruthers J. Management of injected hyaluronic acid induced Tyndall effects. *Lasers Surg Med* 2006;38:202-4.
- Coleman SR. Avoidance of arterial occlusion from injection of soft tissue fillers. *Aesthetic Surg J* 2002;22:555-7.
- Brody HJ. Use of hyaluronidase in the treatment of granulomatous hyaluronic acid reactions or unwanted hyaluronic acid misplacement. *Dermatol Surg* 2005;31:893-7.